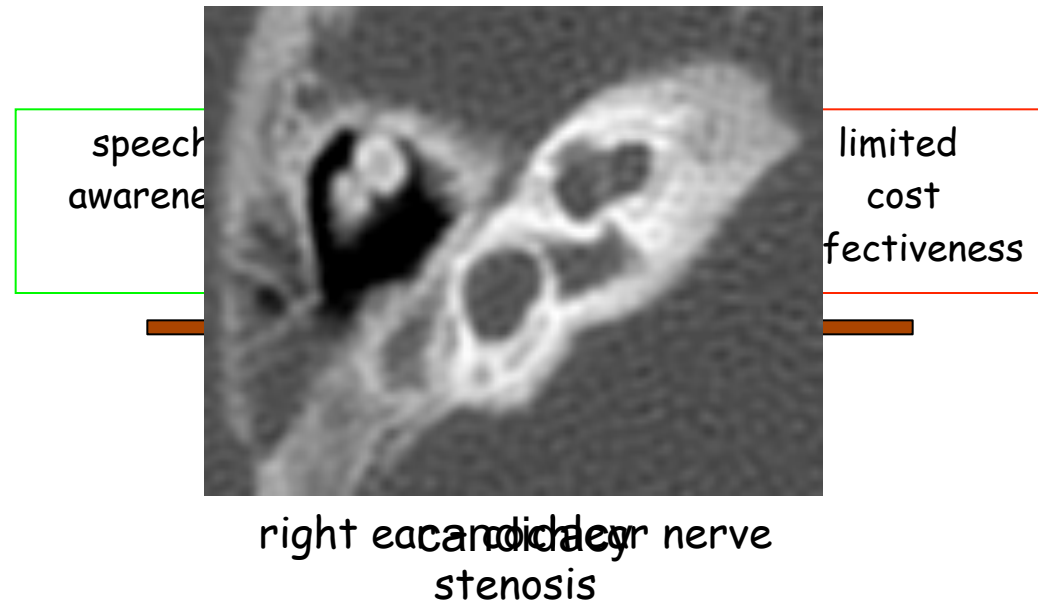
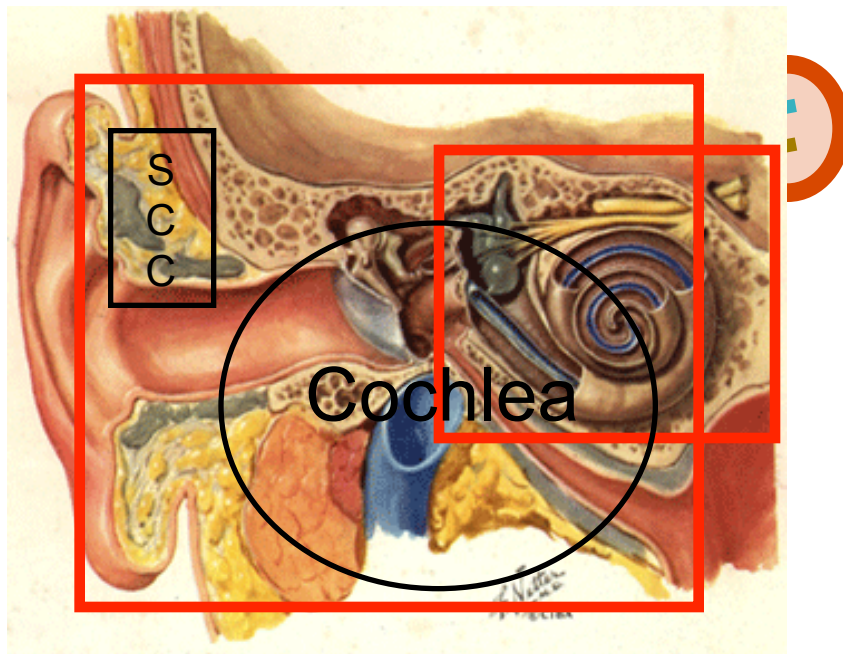


# Narrow Nerve

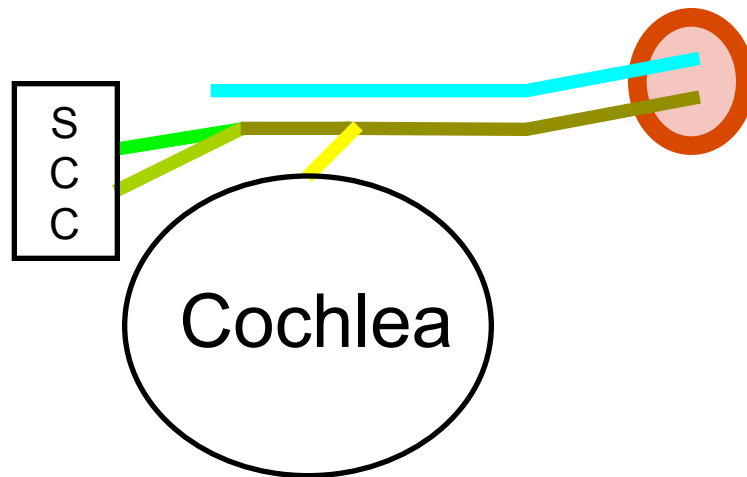
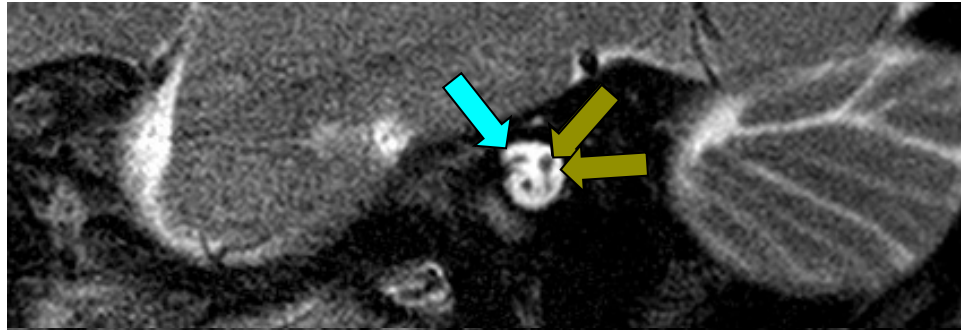
- surgical outcome
- diagnostic accuracy



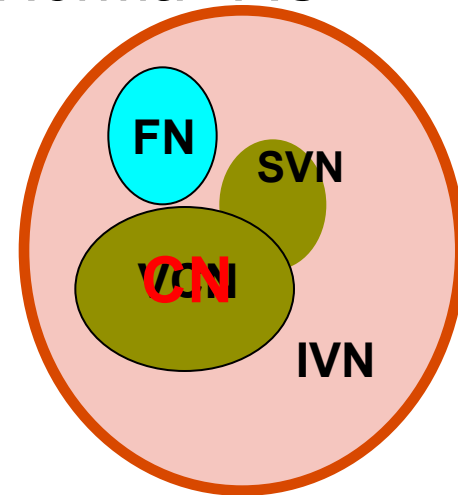
# Normal Internal Auditory Canal



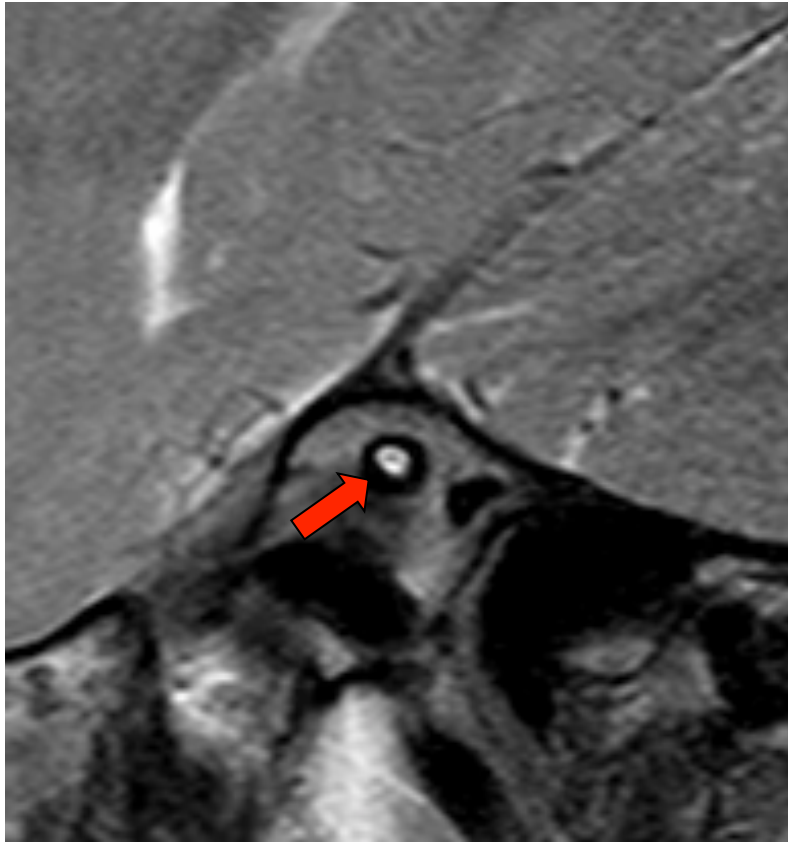
# Normal Internal Auditory Canal



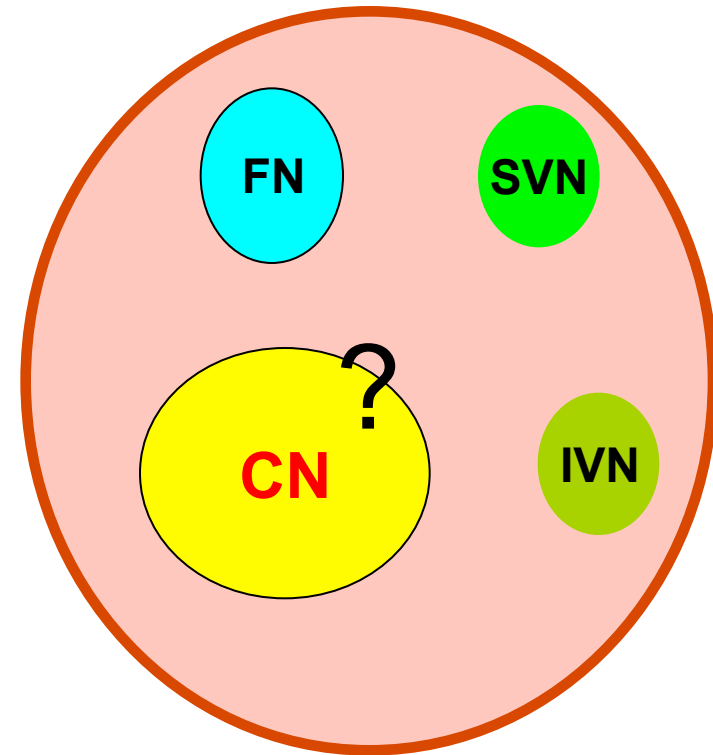
Normal IAC



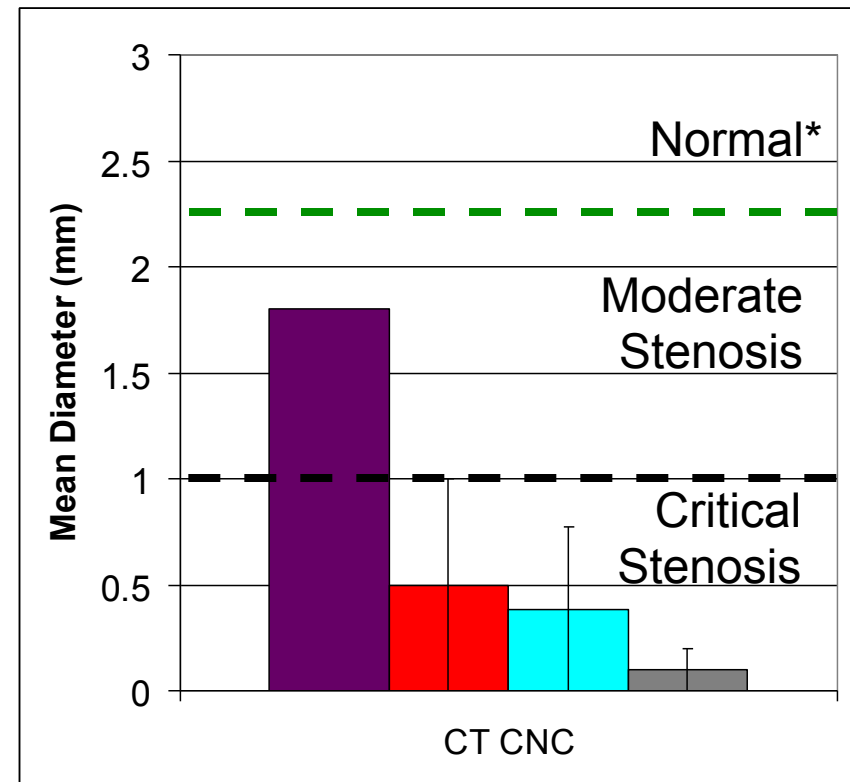
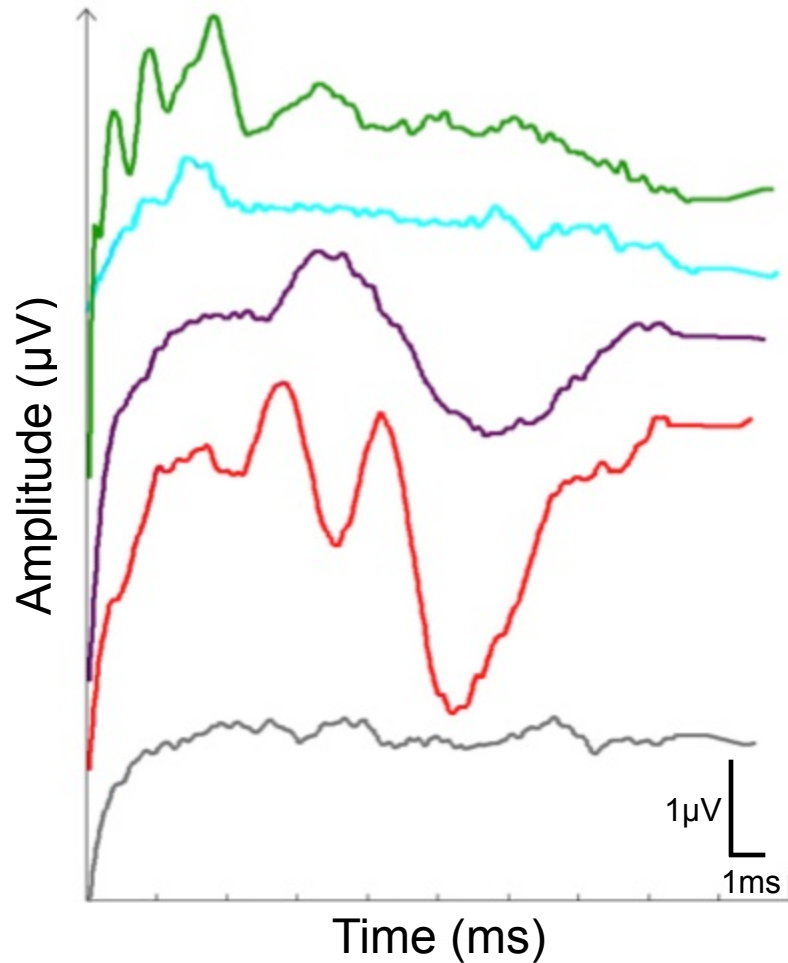
# Stenotic IAC – Functional Nerves?



Stenotic IAC



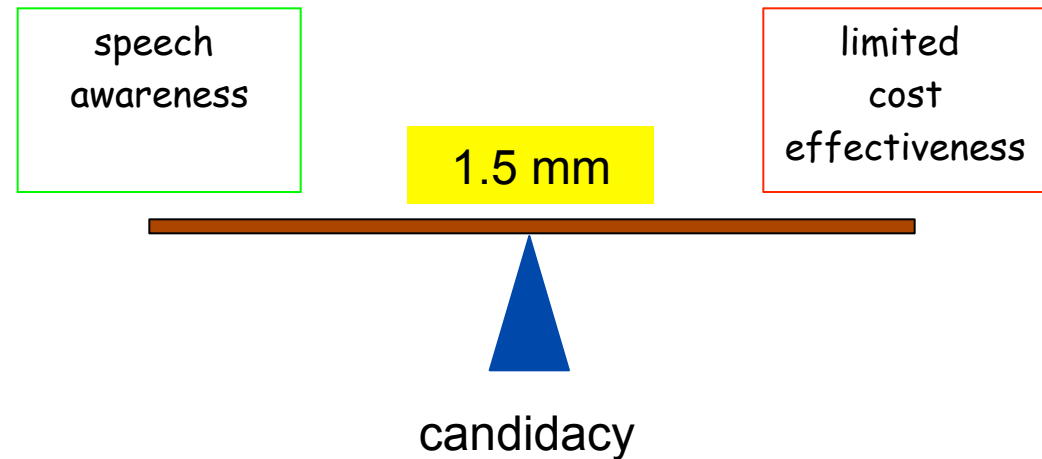
# Cochlear Nerve Canal Diameter



\*Propst et al 2006 Laryngoscope

# Narrow Nerve

- surgical outcome
- diagnostic accuracy



# Current Opinion

- variable outcome
- less than 1.5 mm nerve – very poor performance
- high rate of unwanted stimulation
- possible role for ABI